

GODDARD
VETERINARY
GROUP

Clare Rusbridge BVMS DipECVN MRCVS
European and RCVS and European Specialist In Veterinary Neurology
Stone Lion Veterinary Centre
41 High Street,
Wimbledon,
London, SW19 5AU
Tel: +44 (0)208 946 4228
E-mail: neuro.vet@btinternet.com

Date: 23/04/2009

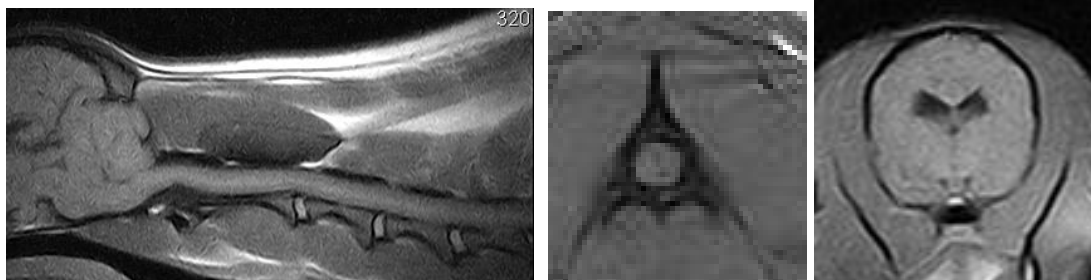
To whom it may concern:

This is to confirm that on the above date the magnetic resonance images (MRI) of **Angel's Pride (D) Jamiroquoi** KLHZB 06/0969 obtained on **17th December 2008** were reviewed

Blenheim CKCS, male , DOB **11th June 2006**, microchip **276098100740431**
Owner – **A.C. Wienk Esbeukman**

These images reveal:

Chiari malformation of the caudal skull	YES
Dilatation of the central canal / syringomyelia	NO
Ventricular dilatation	Mild
NO mucoid material in tympanic bullae	



Using the informal Rusbridge classification the grade of **A** would be attributed to this individual.

Clare Rusbridge BVMS DipECVN MRCVS
RCVS and European Specialist In Veterinary Neurology

